



Patient

NHS No

D.O.B.

Patient Ref

Reason

Ulceration

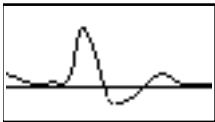
Outcome

disease mild, Obscured, Poor images, Oedema

Right

130

1.00



Good

Brachial

Common Femoral

Good

High Thigh

Low Thigh

Popliteal

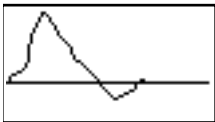
Good

High Calf

140

1.08

Peroneal



Good

130

1.00

Anterior Tibial

Good

Posterior Tibial

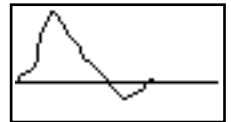
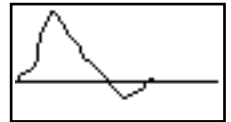
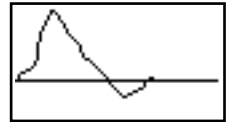
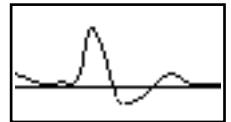
Good

Dorsalis Pedis

Toe Pressure

Post Exercise

Left



Notes

LEFT LOWER LIMB ARTERIAL DUPLEX ASSESSMENT

Abdominal aorta appears mildly diseased with calcified plaques, good triphasic waveforms and PSV 55cm/s. The abdominal aorta appears of normal calibre (maximum AP = 1.9cm), with no evidence of focal dilatation or aneurysm identified.

CIA: not identified, obscured by bowel gas.

EIA: difficult to visualise, but where seen appears patent, good biphasic waveforms, PSV 54cm/s.

CFA: appears mildly diseased, good triphasic waveforms, PSV 70cm/s.

Prof A (origin): appears mildly diseased, good biphasic waveforms, PSV 80cm/s.

Assessed by

Lukasz Koprowski

Checked by



Patient

NHS No

D.O.B.

Patient Ref

SFA: appears patent throughout its length, with minimal mild (diffuse) disease, good biphasic waveforms, PSV 50-81cm/s.

Pop A: appears mildly diseased, good biphasic waveforms, PSV 61cm/s. TPT appears patent; origins of 3 vessel run-off noted.

PTA: appears patent and calcified, good biphasic waveforms, PSV 52cm/s.

ATA: appears patent and calcified, good biphasic waveforms distally, PSV 59cm/s.

Pero A: not identified.

Right CFA: appears mildly diseased, good triphasic waveforms, PSV 130cm/s.

Bilateral, resting ABPIs are within normal levels. Unable to assess left post-exercise ABPI due to limited compliance.

Assessed by

Lukasz Koprowski

Checked by
